

Dermal infusion can be tailored to the individual patient and can be used when conventional microdermabrasion is contraindicated

Skin Management: A Practical Approach

by Lawrence S. Moy, MD, with Catherine Maley, MBA

Although traditional particulate microdermabrasion is widely used, health risks, including pulmonary inhalation and eye irritation, are areas of concern. The skin is abraded with a stream of crystals, such as aluminum oxide sapphire, that are delivered under pressure across the face to remove the upper dermal layer. Studies have shown that microdermabrasion is a superficial peel that can be repeated at 2-week intervals because the skin recovers histologically within 1 to 4 days.¹

Microdermabrasion works for many skin ailments, but it has its limitations. It is contraindicated in patients with active skin infections, such as flat warts, impetigo, and herpes simplex. Patients with malignant skin tumors involving keratoses or other specific keratoses, or those who have used isotretinoin within the past year, also should not be treated with microdermabrasion.²

Enter dermal infusion, or “wet microdermabrasion,” an innovative procedure that provides noninvasive exfoliation and delivers skin-specific topical solutions under pressure to treat such concerns as rosacea, dehydration, acne, and post-inflammatory hyperpigmentation.

The Market Demand

Business 2.0 magazine reports that Americans spent more than \$12.5 billion in 2005 on aesthetic procedures, the

majority of them noninvasive.³ It also estimates that the Baby Boomer population and America’s “makeover” culture may have increased that number to \$20 billion by the end of 2006. Every year, the American Society of Plastic Surgeons’ statistics show that microdermabrasion is one of the top five noninvasive procedures performed.

Suffice to say, there is a huge demand for noninvasive “lunchtime” methods for skin rejuvenation with little to no downtime, especially if those procedures are customized to patients’ individual skin concerns. Dermal infusion offers that customized rejuvenation.

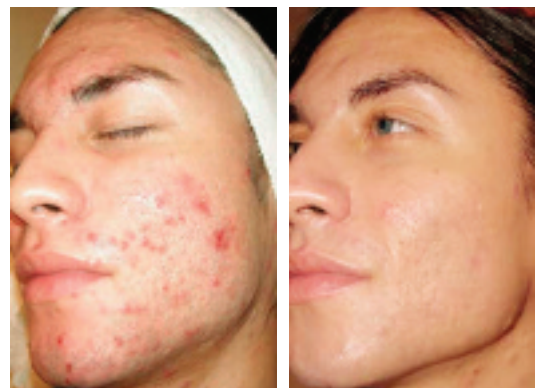How It Works

The patented handpiece consists of an interchangeable treatment head containing medical-grade diamonds in one of several grit sizes embedded in a translucent plastic tip. When the handpiece is brought into contact with the skin, a vacuum is formed that functions to pull the tissue through the plastic tip and into contact with the treatment head. As the handpiece is drawn over the skin, the treatment head simultaneously exfoliates and infuses the condition-specific serums.

Each solution to be infused is selected specifically for the patient’s underlying condition. The vacuum and flow rate are carefully regulated (Figure 1). The slow, even strokes used in the treatment allow for the ancillary benefits of lymphatic, muscle, and motor-nerve point stimulation.

Dermal infusion allows maximal delivery of the agents for treating acne, pigmentation, aging, and rosacea.² For optimum results, and depending on the patient’s skin condition, four to six treatments can be performed every 2 weeks, followed by monthly maintenance treat-

Before & After



This 20-year-old patient with serious type 2 acne received six dermal-infusion treatments, each 2 weeks apart. He is shown before the first treatment and immediately after the final treatment. Courtesy of Gideon Kwok, MD.

Skin Management: A Practical Approach

ments. The treatment is safe and painless, and results are visible immediately as well as over time.

Microdermabrasion is often too aggressive for acne-prone or sensitive skin, whereas dermal infusion is so unobtrusive that even dry skin, a contraindication for particulate microdermabrasion, is effectively treated.

A Dermal-Infusion Study

To better understand the differences between traditional microdermabrasion and dermal infusion, I conducted a histological observational study.

The dermal-infusion technique was studied on volunteers who were preparing for elective facelift procedures. Each patient was pretreated 1 to 3 days before the procedure. The preauricular area was treated with the dermal-infusion system. The skin was carefully marked and treated as outlined below.

During the facelift procedure, the dermal infusion-treated skin was dissected away. The sampled area was placed into bottles with 10% formalin. The tissue samples were sent for preparation processing by embedding onto paraffin sections and sectioning with a microtome. The sections were then stained for hematoxylin and eosin. The specimens were evaluated by a dermatopathologist. A calibrated micrometer was used to measure depths of effect from treated tissue.

Study Results

I reported the following in this unpublished study: "The results showed patients achieved immediate, optimum results. The results demonstrated that the dermal infusion system evenly abrades the superficial epidermis. All of the reviewed specimens demonstrated

even abrasion with similar depths of effect. Histologic studies revealed a uniform, even abrasion to the depth of 30 to 35 micrometers (Figures 2 through 6). The abrasion was maintained in the granular layer of the epidermis. The majority of the epidermal integrity, including the basement membrane and superbasal layer, remained intact. Treated areas demonstrated regrowth of the superficial epidermal layers within 2 days.

"Patients in the study also received immediate exposure of the abraded skin to the fluid, demonstrating an interesting effect. The keratinocytes show marked swelling from hydration. The upper papil-

lary dermis also demonstrates edema around the collagen fibers and around the vascular structures.

"Traditional microdermabrasion is limited to mildly exfoliating the epidermis. Microdermabrasion is analogous to a superficial peel in both depth and complications. Microdermabrasion can be repeated at 2-week intervals because the superficial epidermis recovers within 1 to 4 days.¹ Studies with dry, crystal microdermabrasion done weekly demonstrate histologic and microscopic improvement in photoaging and intrinsic aging.^{4,5} The aforementioned studies illustrate that skin texture, pigmentation, skin atrophy, oiliness, dilated pores, laxity, and telangectasias can be improved with weekly microdermabrasions.

"The dermal infusion system provides the efficacy of the traditional microdermabrasion. It provides the soothing effects of a delivery system that reduces irritation and erythema while delivering solutions that treat and may prevent progression of the underlying condition. The effects are both efficacious and aesthetically elegant.

"The innovative dermal infusion system with the patented, multi-dimensional handpiece minimizes or eliminates all of the potential complications such as irritation, erythema and xerosis that often arise from traditional microdermabrasion, chemical peels and other exfoliative procedures."

What the Study Shows

The study proves that dermal infusion is a safe procedure for lightly abrading the skin and allows for even treatment across the facial skin.

Dermal infusion can be used with various solutions for ideal treatments. It allows maximal delivery of the agents for acne, pigmentation, and aging. These solutions greatly

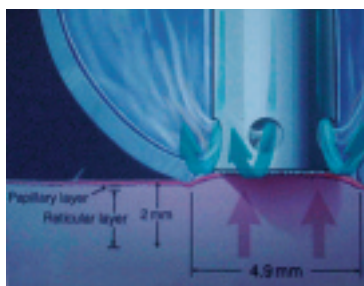


Figure 1. Handpiece in contact with the skin with the effect of even abrasion, fluid flow, and vacuum. The skin is brought past the diamond fraise in the presence of the fluid. Courtesy of Emed Inc.

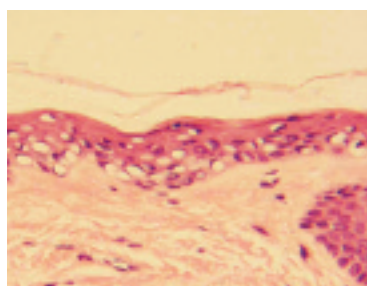


Figure 2. Dermal infusion provides uniform abrasion to the depth of 30 to 35 μm within the epidermis on preauricular skin. The stratum corneum is removed, and portions of the granular layer are also removed in sections.

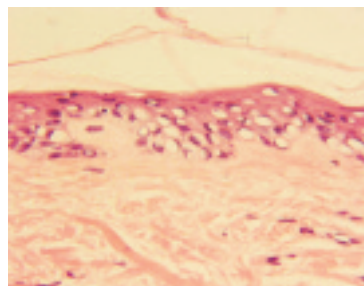


Figure 3. Vacuolization of the keratinocytes and margination of the nuclei. This effect is consistent with rapid hydration of the keratinocytes.

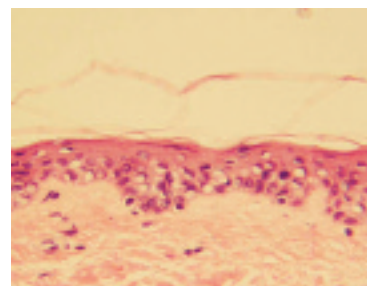


Figure 4. In specific sections, there is regrowth of the granular layer and the stratum corneum. Edema of the papillary dermis is resolving.

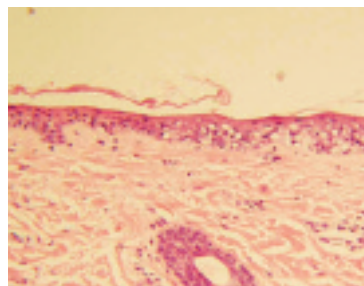


Figure 5. The edge of treatment for dermal infusion (right) and untreated epidermis (left). The hydration effect is dramatically shown by the enlarged keratinocytes with the displaced nuclei on the treated areas compared to the untreated areas. Also, the rapid hydration effect has increased the dermal-infusion-treated epidermal thickness by 70%.

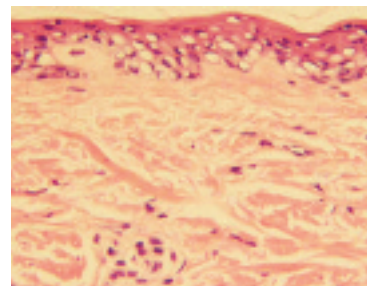


Figure 6. Wide spaces between the collagen bundles and swollen vascular structures demonstrate papillary dermal edema. Dermal edema was present after 1 day, suggesting solution delivery to the papillary dermis. Histology images courtesy of Lawrence S. Moy, MD.

Skin Management: A Practical Approach

increase the efficacy of the procedure.

The histology demonstrates an ideal, immediate delivery of active solutions

introduced for wound healing, photodamage, and acne treatment. A trend toward using these light-based systems

in combination with microdermabrasion is also emerging.

Dermal infusion is the latest innovation in the area of microdermabrasion and has positioned itself as an effective and proven

clinical procedure in the aesthetic world. Research is under way to find many exciting new developments and applications for the dermal-infusion system. **PSP**

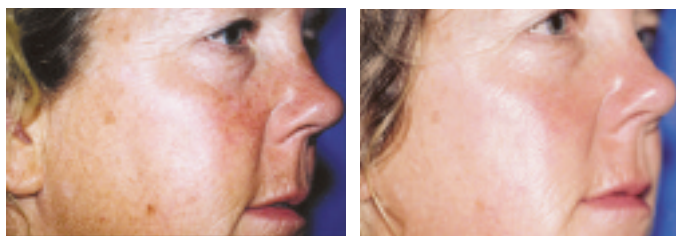Lawrence S. Moy, MD, is a cosmetic dermatologist who practices in Manhattan Beach, Calif. He is currently on staff at UCLA Medical Center in Los Angeles and at Harbor-UCLA Medical Center in Torrance, Calif, and teaches residents from the Western University College of Osteopathic Medicine in Pomona, Calif. His dermatological practice emphasizes cosmetic surgeries and procedures as well as general dermatology. He can be reached at (310) 546-7780.

Catherine Maley, MBA, is president and senior marketing strategist of Cosmetic Image Marketing in San Francisco. Her firm specializes in helping aesthetic practices grow using public relations, advertising, and strategic marketing strategies. She can be reached at (866) 563-3332 or via her Web site, www.cosmeticimagemarketing.com.

References

1. Hernandez-Perez E, Ibiert EV. Gross and microscopic findings in patients undergoing microdermabrasion for facial rejuvenation. *Dermatol Surg.* 2001;27:637-640.
2. Desai T, Moy L, Kirby W, et al. Evaluation of the SilkPeel™ system in treating erythematotelangiectatic and papulopustular rosacea. *Cosmetic Dermatol.* 2006;19: 51-56.
3. Esfahani E. The new skin trade. *Business 2.0.* February 5, 2006. Available at: http://money.cnn.com/magazines/business2/business2_archive/2006/01/01/8368124/index.htm. Accessed December 4, 2006.
4. Coimbra M, Rohrich RJ, Chao J, Brown SA. A prospective controlled assessment of microdermabrasion for damaged skin and fine rhytides. *Plast Reconstr Surg.* 2004;113:1438-1443; discussion 1444.
5. Karasiuk KB, inventor; Emed Inc, assignee. Microdermabrasion system and method of use. US Patent 6 695 853. February 24, 2004.
6. Svane-Knudsen V, Halkier-Sorensen L, Rasmussen G, Ottosen PD. Altered permeability barrier structure in cholesteatoma matrix. *Eur Arch Otorhinolaryngol.* 2002; 259:527-530.
7. Shpall R, Beddingfield FC, Watson D, et al. Microdermabrasion: A review. *Facial Plast Surg.* 2004;20:47-50.

Before & After



This 38-year-old patient with postinflammatory hyperpigmentation received eight dermal-infusion treatments, each 2 weeks apart. She is shown before the first treatment and immediately after the final treatment. Courtesy of Gregory Keller, MD.

for treatments. Removing the stratum corneum and the upper layer of the granular layer removes the Odland bodies.⁶ Odland bodies are impacted membrane bodies that are compressed membrane materials residual from cell organelles. Odland bodies are an important barrier that functions to limit transepidermal water loss.^{4,7} By temporarily lifting off the Odland bodies, the cells undergo hydration.

Additional studies are currently under way to determine the efficacy of exfoliation and infusion of skin-specific topicals for other skin concerns such as psoriasis and eczema. In other advances, new light-based diode systems with handpieces that emit red (600-nm to 700-nm) as well as blue (430-nm) light have been